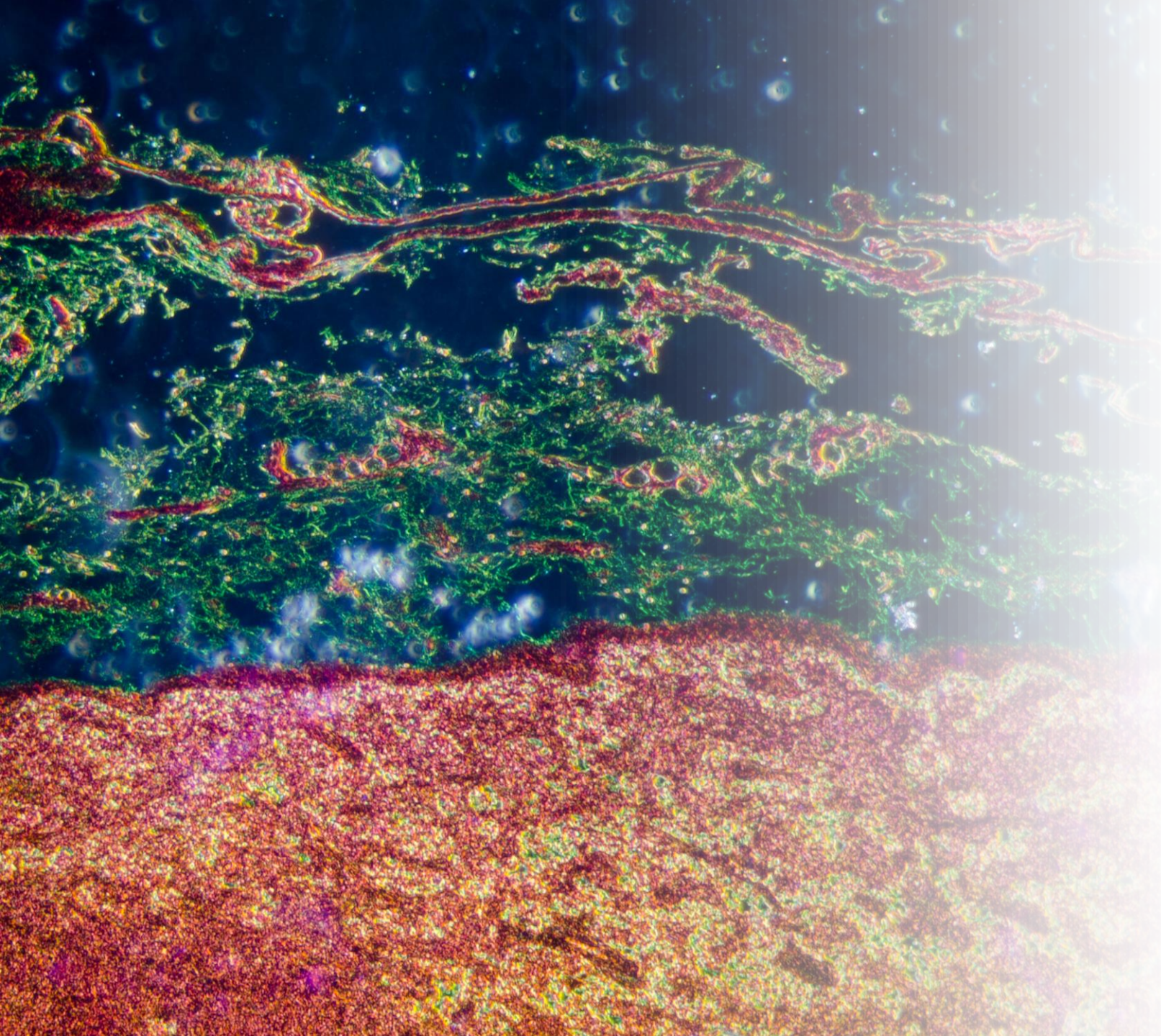


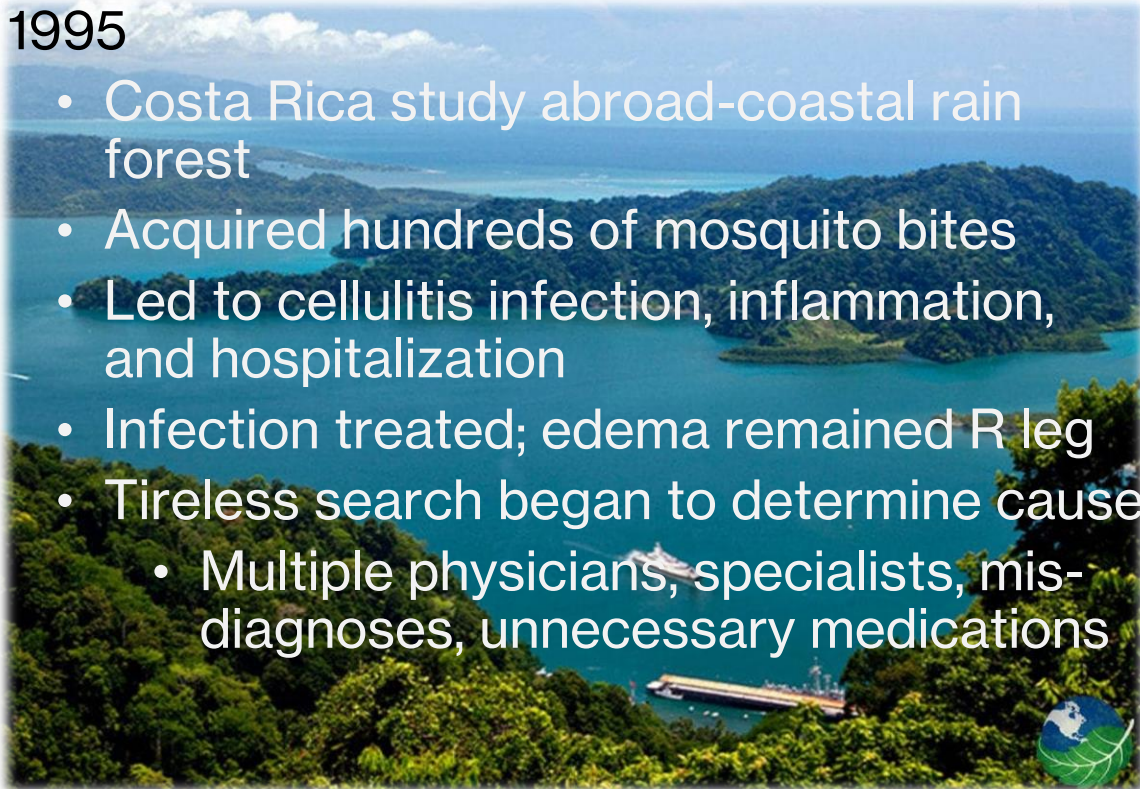
Rebecca's Lymphedema Journey

25 years from symptoms to I VA



23 years in 2 minutes!

- 1980 Born in Atlanta
 - Active childhood - sports and ballet
- 1995
 - Costa Rica study abroad-coastal rain forest
 - Acquired hundreds of mosquito bites
 - Led to cellulitis infection, inflammation, and hospitalization
 - Infection treated; edema remained R leg
 - Tireless search began to determine cause
 - Multiple physicians, specialists, mis-diagnoses, unnecessary medications
- 1999
 - Lymphedema diagnosis-searching on the world wide web
 - Complete Decongestive Therapy
- 1999-2017
 - Day/night garments, MLD, healthy lifestyle
 - Certified Lymphedema Therapist 2013
 - Edema worsened-2nd pregnancy
 - Presented at lymphedema conference- met Dr. Chen
- 2018
 - Initial assessment with Dr. Chen
 - Near-Infrared Fluorescence (NIRF) Lymphography; aka Indocyanine Green (ICG) lymphography



My Lymphedema Management

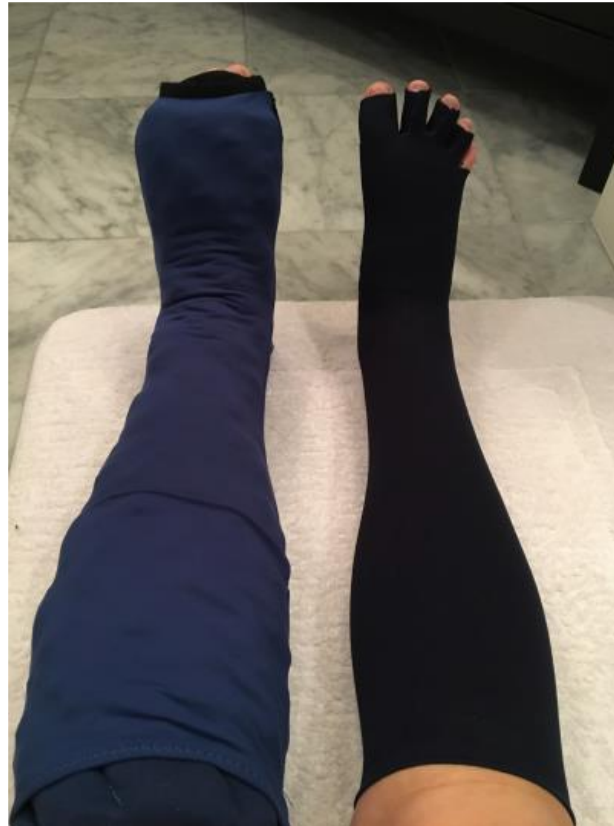Flat knit garments
(day)



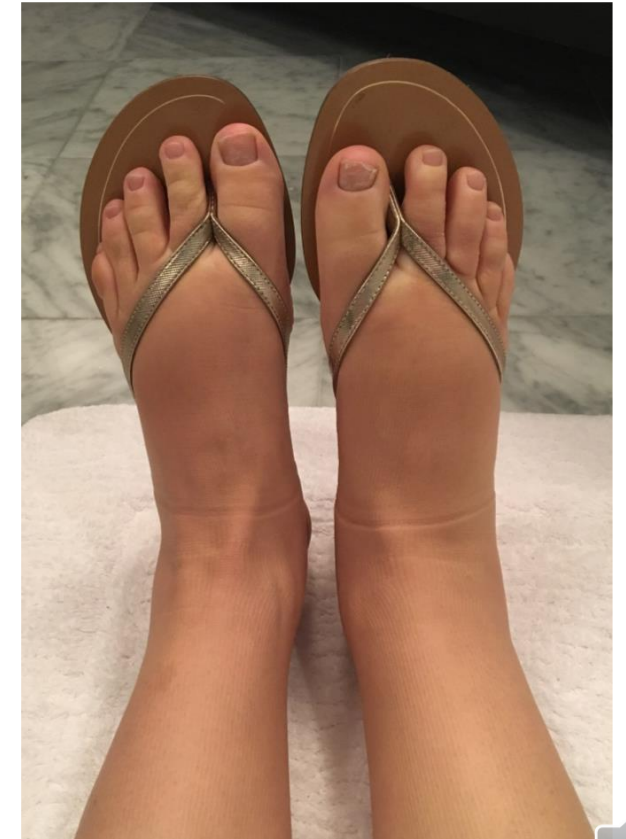Chip foam garments
(night)



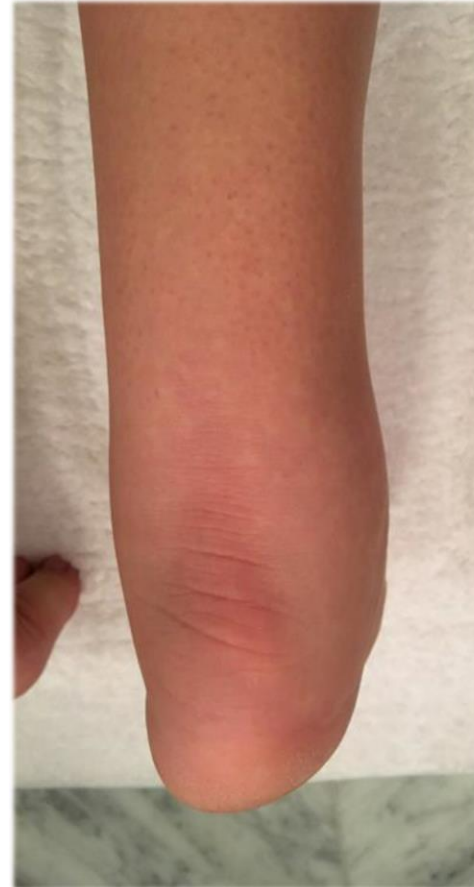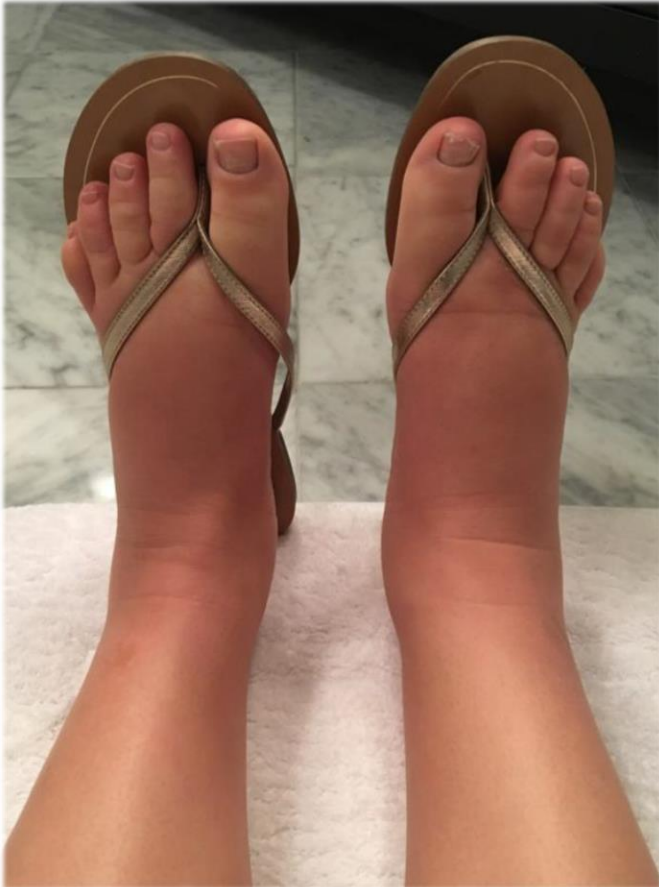Garments on



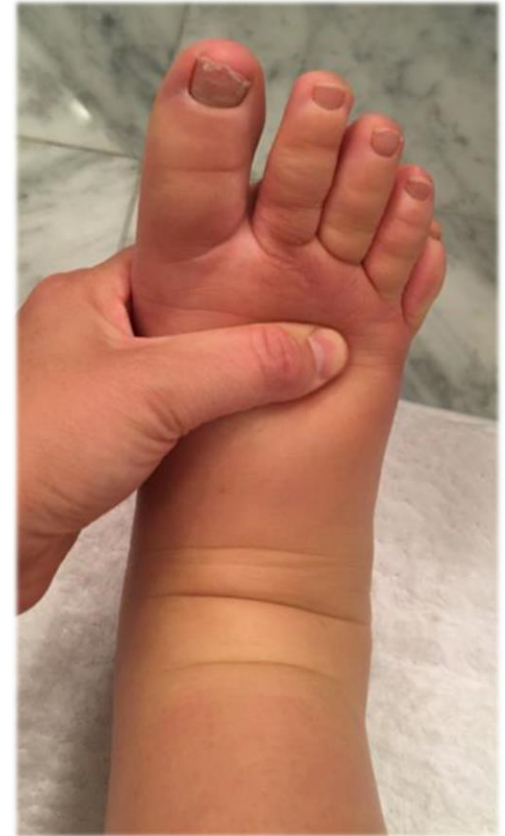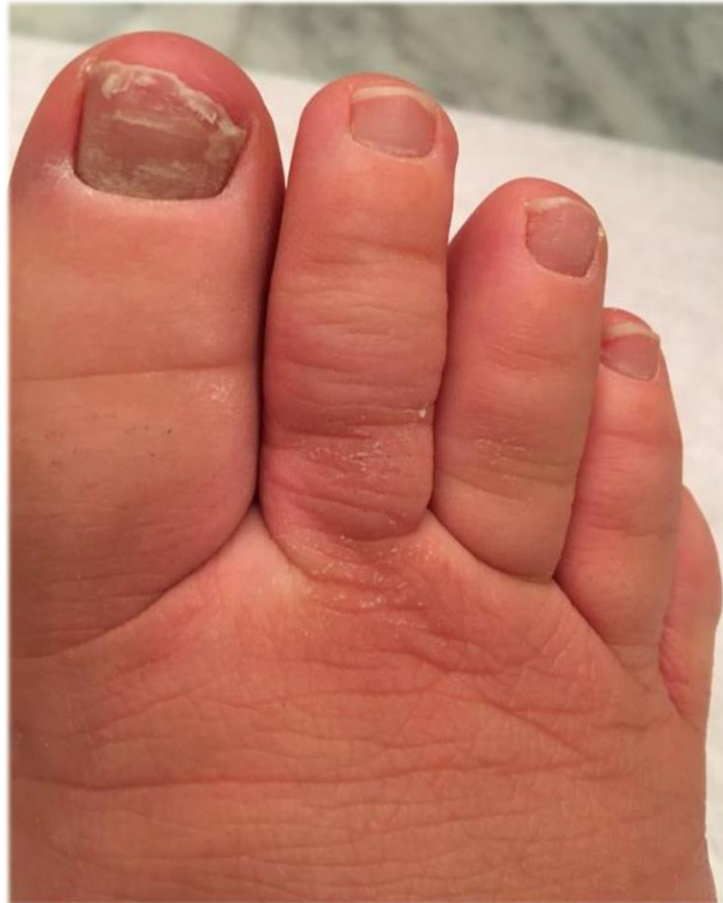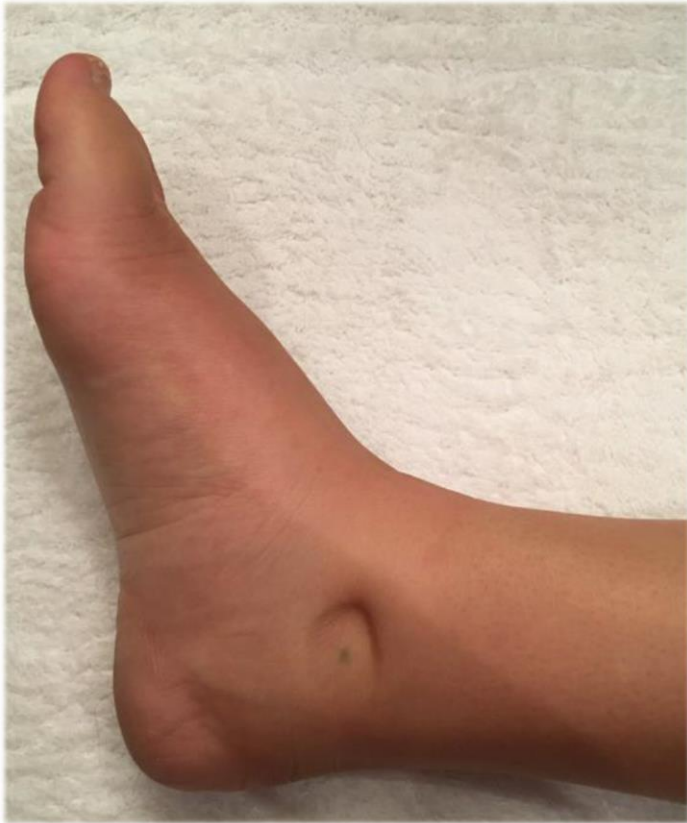Garments *just* removed



1 hour after garment removal

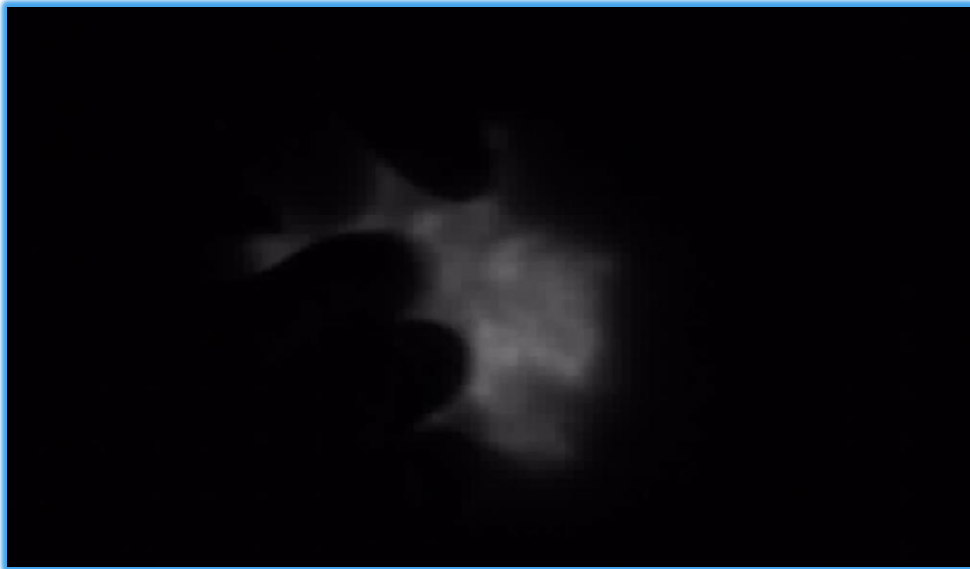

1 hour after garment removal




Near-Infrared Fluorescence (NIRF) Lymphography: Lower Extremities

Initial Right Leg



Delayed
Right Leg



Delayed
Left Leg



Near-Infrared Fluorescence (NIRF) Lymphography: Left Upper Extremity

Initial Scan Left Arm



Delayed Scan Left Arm

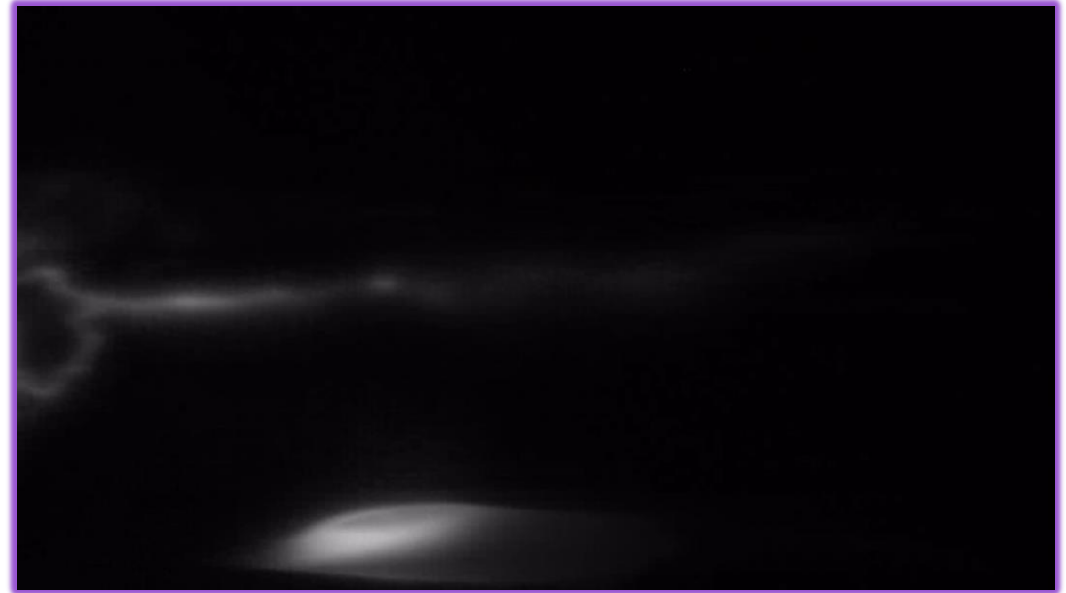


Near-Infrared Fluorescence (NIRF) Lymphography: Right Upper Extremity

Initial Scan Right Arm



Delayed Scan Right Arm

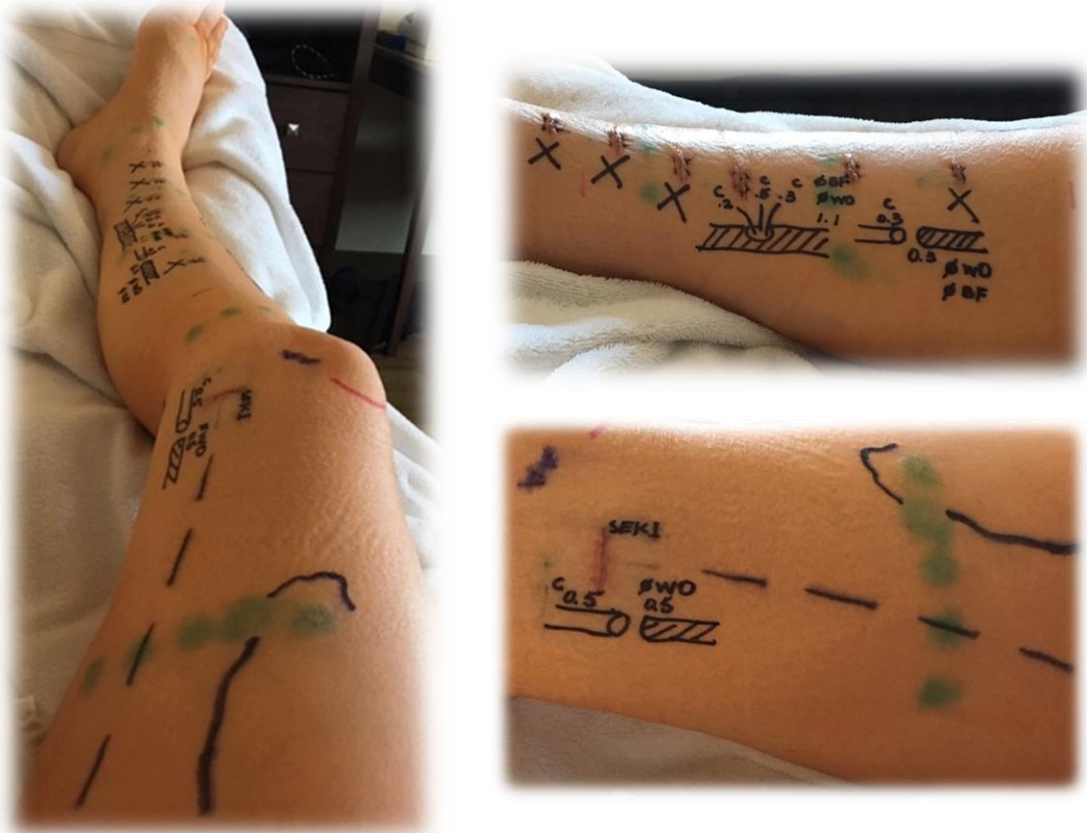

Conclusions from NIRF Lymphatic Imaging

- ICG lymphographic findings consistent with congenital lymphedema of all 4 extremities
 - Dermal backflow and star dust patterns; very few linear patterns
- Moderate clinical presentation
- ICG lymphography indicated severe lymphatic hypoplasia
- Right arm is the most preserved and has the highest chance of successful LVA surgery
- Decision to move forward with LVA

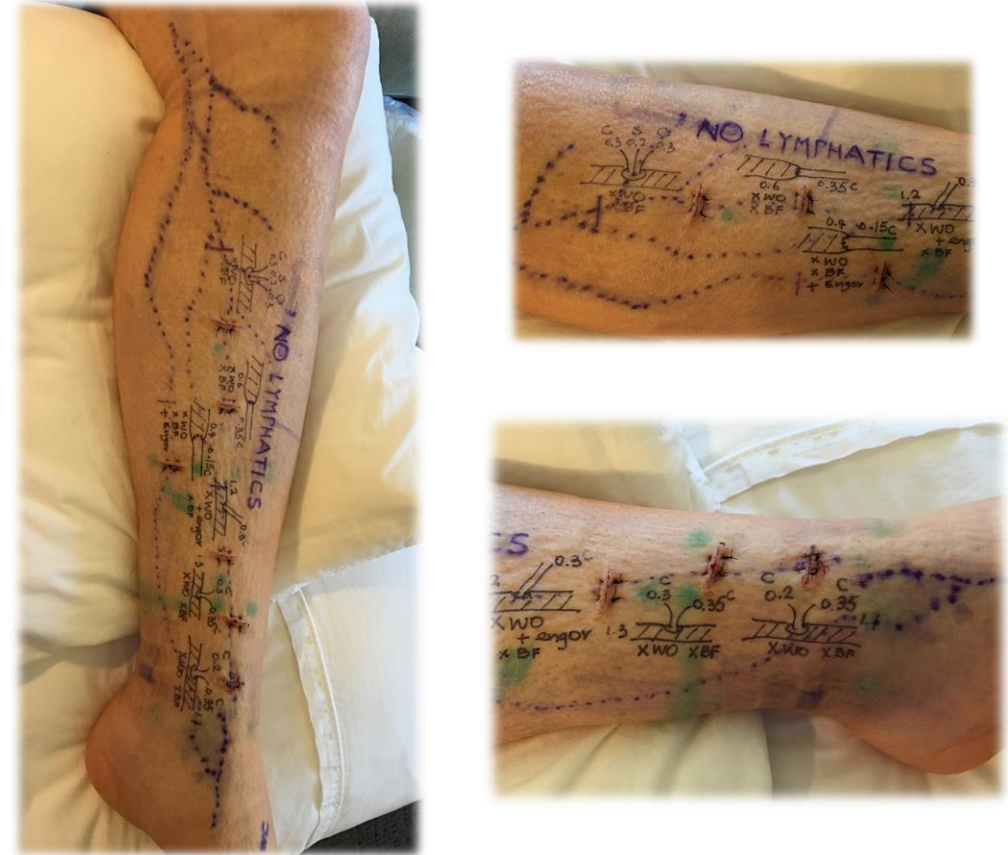

April 2019-Right Leg



7 incisions with
5 LVA connections

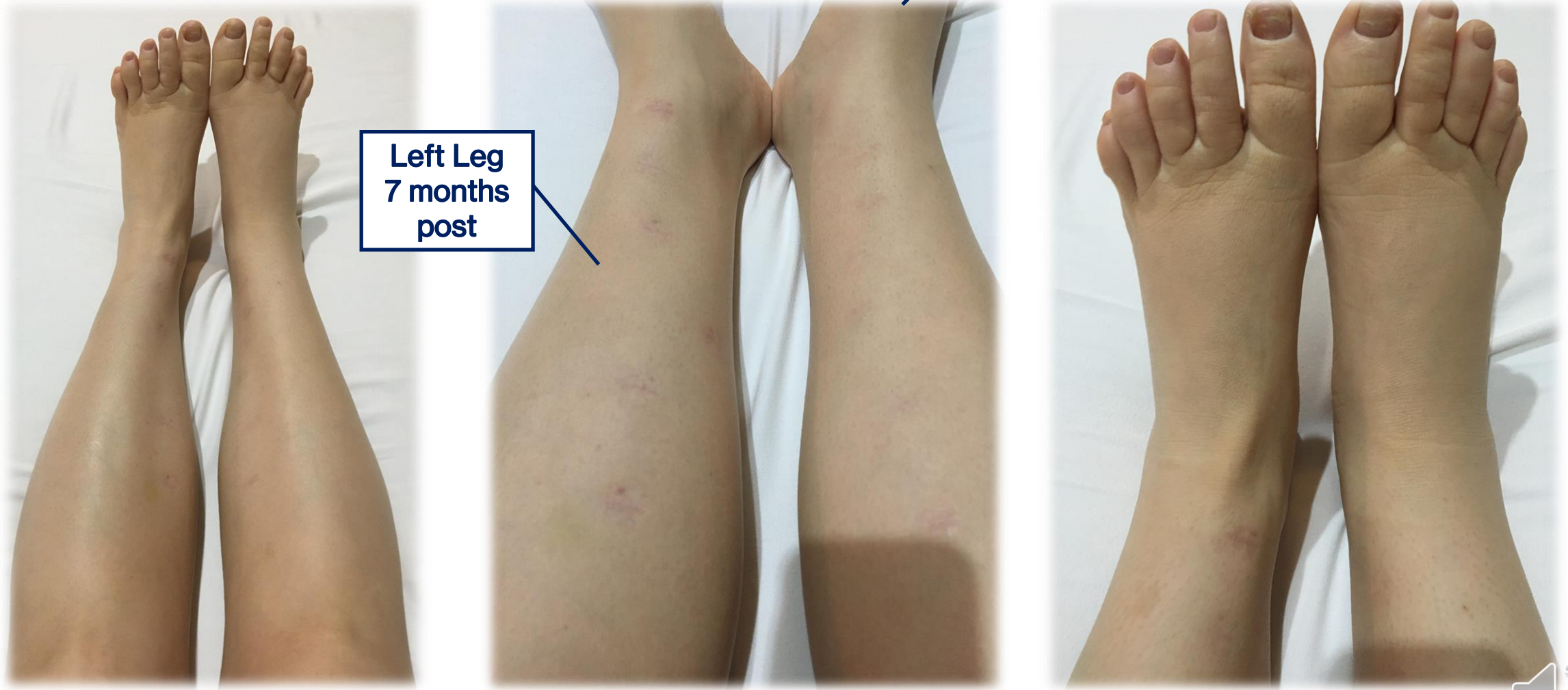
October 2019-Left Leg



5 incisions with
10 LVA connections



MAY 2020- Lower Extremities

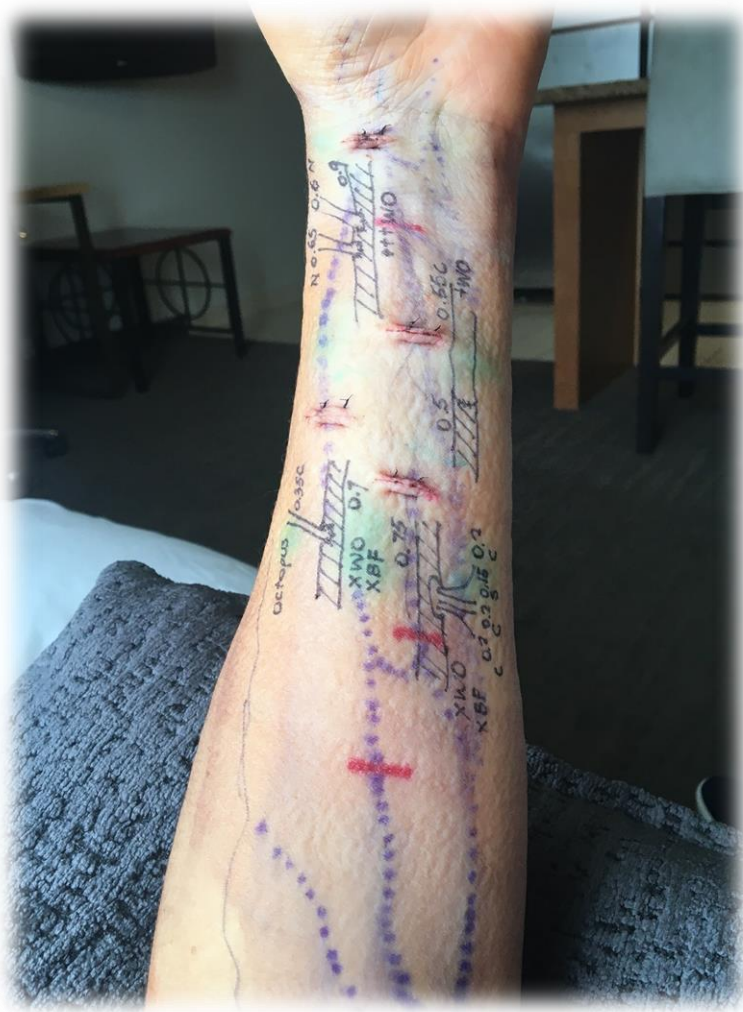

Left Leg
7 months
post

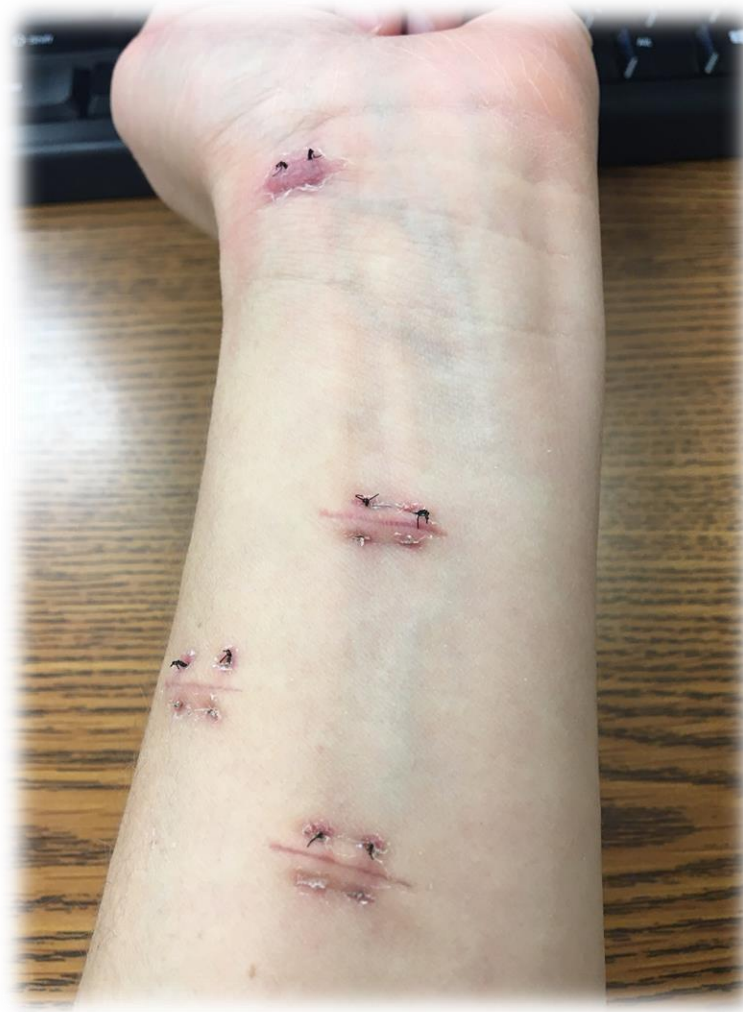Right Leg
13 months
post



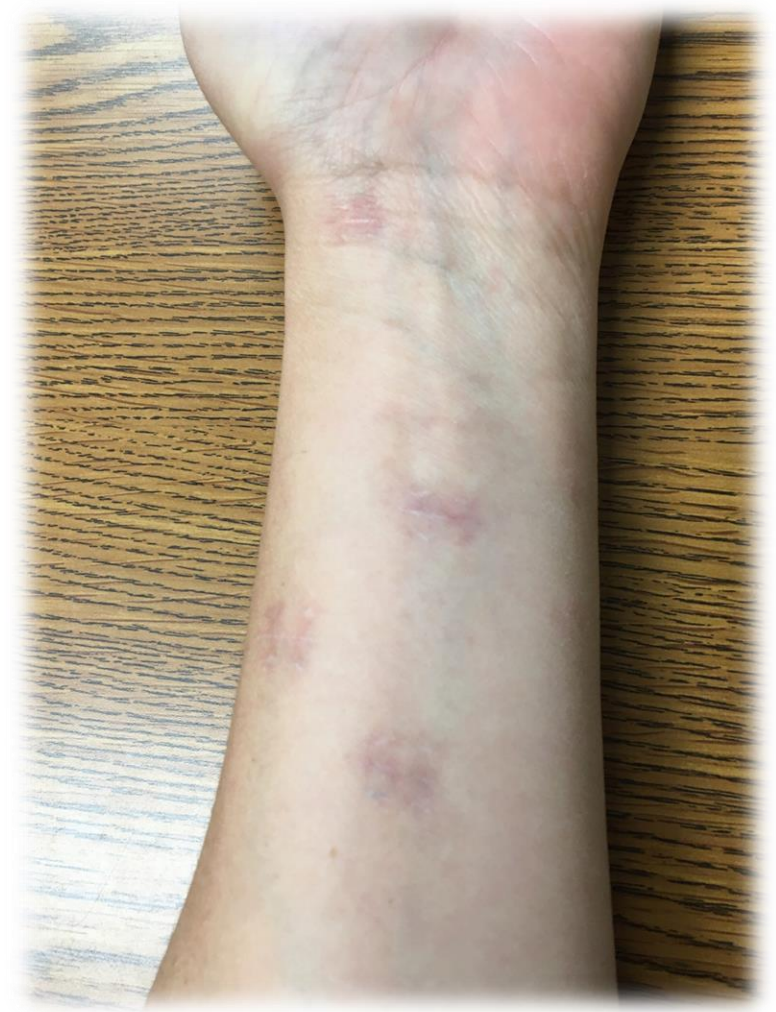NOV 2019



DEC 2019



SEPT 2020



**Thank you for inviting me to share a glimpse into
my journey with lymphedema**

